

See discussions, stats, and author profiles for this publication at: <https://www.researchgate.net/publication/299395050>

# A comparative study of lingual mucosal graft urethroplasty with buccal mucosal graft urethroplasty in urethral stricture disease: An institutional experience

Article in *Urology Annals* · April 2016

DOI: 10.4103/0974-7796.172214

---

CITATIONS

0

---

READS

5

3 authors, including:



**Dilip Kumar Pal**

Institute of Post-Graduate Medical Education...

211 PUBLICATIONS 179 CITATIONS

SEE PROFILE



**Bastab Ghosh**

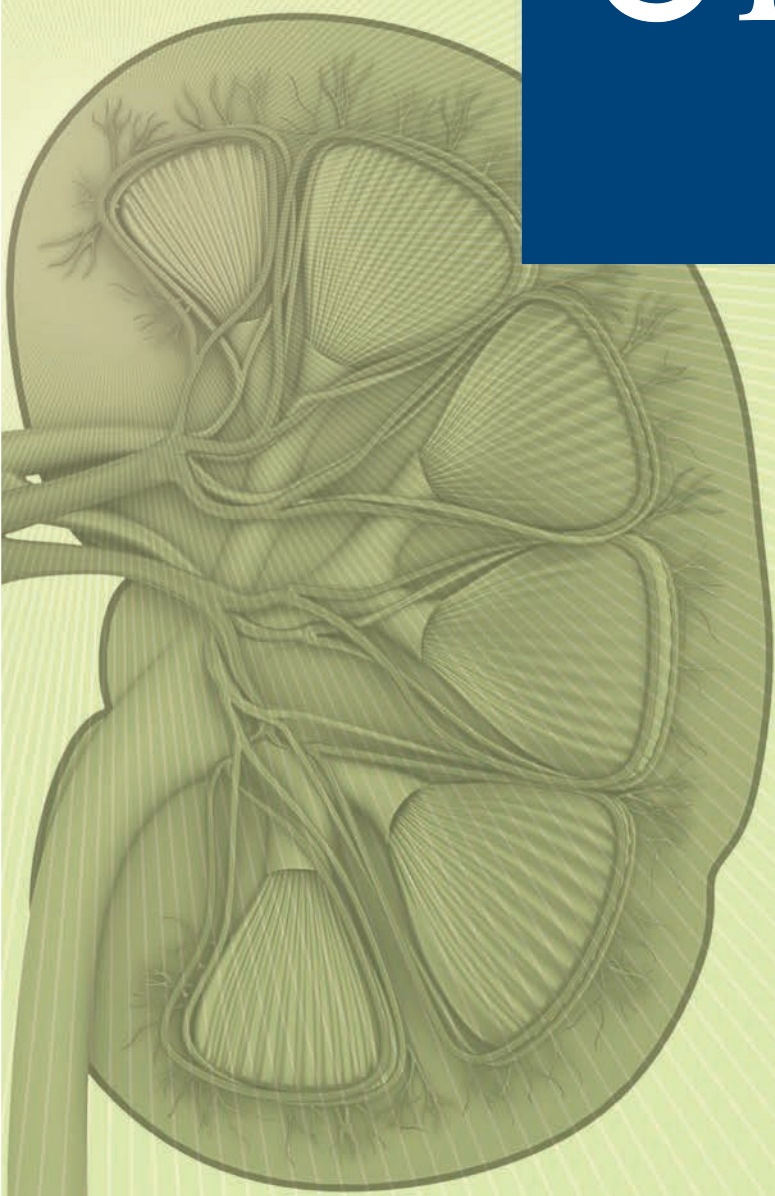
Institute of Post-Graduate Medical Education...

45 PUBLICATIONS 11 CITATIONS

SEE PROFILE

# UROLOGY ANNALS

Online full text at [www.urologyannals.com](http://www.urologyannals.com)



Official Publication of  
**The Saudi Urological Association**

Volume 8 ■ Issue 2 ■ April 2016

# A comparative study of lingual mucosal graft urethroplasty with buccal mucosal graft urethroplasty in urethral stricture disease: An institutional experience

Dilip Kumar Pal, Depak Kumar Gupta, Bastab Ghosh, Malay Kumar Bera

Department of Urology, Postgraduate Institute of Medical Education and Research, Kolkata, West Bengal, India

## Abstract

**Aims:** A prospective study to compare the outcomes of lingual versus buccal mucosal graft urethroplasty in patients with long segment anterior urethral strictures disease.

**Materials and Methods:** The study included 30 patients for buccal mucosal graft urethroplasty (group I) and 30 patients for lingual mucosal graft urethroplasty (group II) for treatment of long segment (>3 cm) incomplete anterior urethral stricture disease using single-stage dorsal onlay free oral mucosal graft urethroplasty by Barbagli's technique between February 2013 to September 2014. All patients underwent complete evaluation of the stricture including inspection of the oral cavity.

**Results:** The results of urethroplasty in between two group were not significant ( $P > 0.05$ ) in terms of Qmax ( $P = 0.63$ ), mean postoperative AUA symptom score ( $P = 0.83$ ), operative time ( $P = 0.302$ ) intra operative blood loss ( $P = 0.708$ ), duration of postoperative hospitalization ( $P = 0.83$ ), but slurring of speech complications was seen in group II, but not in group I. Long-term complications of salivary disturbance, tightness of the mouth, persistent pain at graft site, perioral numbness, seen only in group I (BMGU).

**Conclusion:** LMG urethroplasty is an excellent alternative to BMG urethroplasty with comparable results of urethroplasty and minimal donor site complications.

**Key Words:** Buccal mucosal graft urethroplasty, lingual mucosal graft urethroplasty, urethral stricture disease

## Address for correspondence:

Prof. Dilip Kumar Pal, Department of Urology, Postgraduate Institute of Medical Education and Research, 244, AJC Bose Road, Kolkata - 700 020, West Bengal, India. E-mail: drdkpal@yahoo.co.in

Received: 14.06.2015, Accepted: 22.08.2015

## INTRODUCTION

Stricture disease of the urethra is a frequent urological problem in India, posing a big challenge in managing its chronic and recurrent course. The search for ideal graft material for substitution urethroplasty is constantly evolving. For many years, penile skin was the most popular substitution material

used for urethroplasty, but today buccal mucosa is suggested as the gold standard.<sup>[1]</sup>

In the eastern part of India, people have a habit of betel and tobacco chewing. In these persons, the buccal mucosa is often

This is an open access article distributed under the terms of the Creative Commons Attribution-NonCommercial-ShareAlike 3.0 License, which allows others to remix, tweak, and build upon the work non-commercially, as long as the author is credited and the new creations are licensed under the identical terms.

For reprints contact: reprints@medknow.com

**How to cite this article:** Pal DK, Gupta DK, Ghosh B, Bera MK. A comparative study of lingual mucosal graft urethroplasty with buccal mucosal graft urethroplasty in urethral stricture disease: An institutional experience. Urol Ann 2016;8:157-62.

Access this article online	
Quick Response Code:	Website: www.urologyannals.com
	DOI: 10.4103/0974-7796.172214

diseased and unfavorable for substitution urethroplasty. Until now no such prospective comparative study done in this region, so we started using lingual mucosa as a graft for substitution urethroplasty and compared our results with buccal mucosal graft urethroplasty (BMGU). The chief cause of urethral stricture in our study was balanitis xerotica obliterans (BXO), also known as lichen sclerosus atrophicus.

## MATERIALS AND METHODS

After review board clearance, taking proper consent of the patient the study was done from August 2012 to February 2014, 60 men (30 BMGU and 30 lingual mucosal graft urethroplasty [LMGU]) aged 18–58 year with anterior urethral stricture, managed by single-stage free oral mucosal graft substitution urethroplasty, completed at least 6 months of follow-up. Every alternate patient taken for BMGU except the patient who has unhealthy buccal mucosa shifted for LMGU. The exclusion criteria were length of stricture <3 cm, complex stricture requiring multistage urethroplasty, having only metal stenosis or fossa navicularis stricture, oral neuropathy, history of oral malignancy or urethral malignancy, BPE (on ultrasonography and digital rectal examination in patients above 50 years) and patients who did not complete at least 6 months of follow-up after surgery.

All patients were evaluated preoperatively with detailed case history; physical examination uroflowmetry, urethroscopy, and retrograde or voiding urethrography [Figures 2a and 5a], AUA symptom scores were assessed. The oral cavity of all patients was inspected during the initial evaluation.

The criteria for successful repair are  $Q_{max} >15$  ml/s with spontaneous voiding with insignificant postvoid residual urine. Even those cases which had  $Q_{max} <15$  ml/s, but where amenable to minor corrective procedures such as metal dilatation or endoscopic dilatation, and subsequently voided normally with  $Q_{max} >15$  ml/s were included in the success group.

The clinical assessment included the donor site morbidity with evaluation of presence of oral pain, difficulty in opening of mouth and speech, neurosensory deficits, facial deformity, and salivary changes.

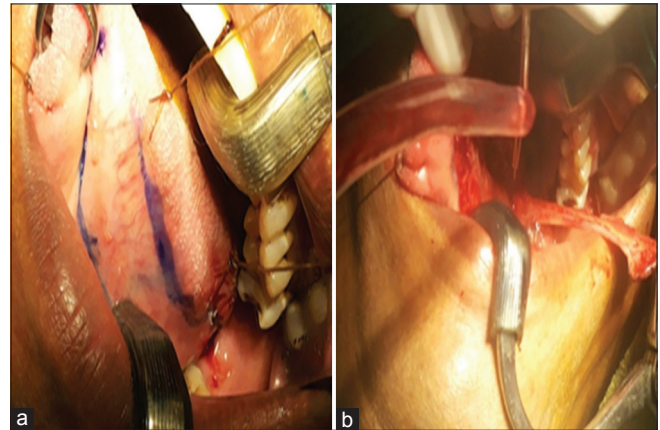
## Procedure

### Urethral mobilization

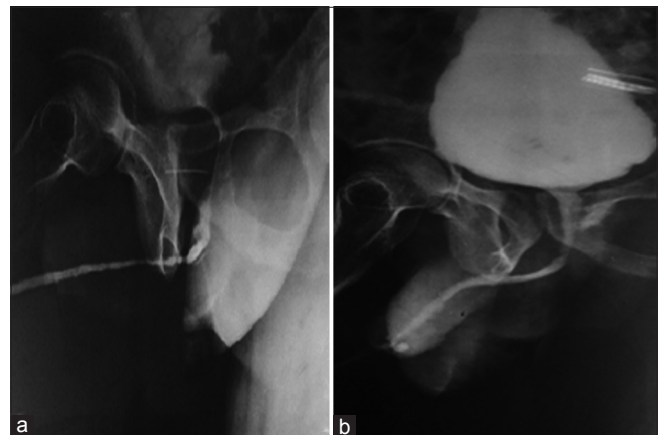
All cases were operated under general anesthesia with nasotracheal intubation. Using a perineal approach, complete mobilization of the strictured segment was done. Urethrotomy was performed over the dorsal aspect and extended into the healthy urethra around 1 cm on each side.

### Graft harvesting

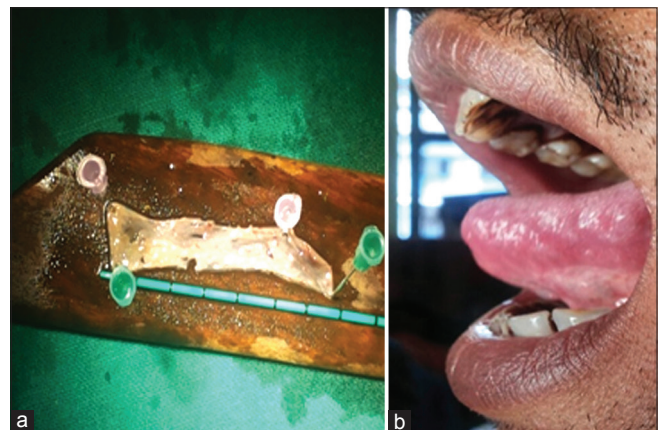A stay suture was taken at the tip of the tongue for traction. Then the length of graft required was marked on the ventrolateral



**Figure 1:** (a and b) Lingual mucosa harvesting from ventrolateral aspect of tongue



**Figure 2:** (a) Preoperative retrograde urethrogram of a patient showing pan anterior urethral stricture plan for lingual mucosal graft urethroplasty. (b) Postoperative retrograde urethrogram after lingual mucosal graft urethroplasty



**Figure 3:** (a) Lingual mucosal graft. (b) Lingual mucosa harvest site after 1-month

aspect of the tongue from its posterior part with a width of 1.5 cm. Two stay sutures were taken at the proximal margin of the graft. Full thickness mucosal graft was harvested with a specially designed right angled scissor as per requirement even across the midline to the opposite side of the tongue if required. The harvested graft then immersed in a bowl of normal saline. Then it was processed by removing all submucosal adventitial tissue which is fat-free as described in the literature.<sup>[2,3]</sup> If a longer graft was needed then, then harvesting was also done from the contralateral side of the tongue [Figure 1a and b]. The graft was then tailored according to the length of the stricture. Similarly for the buccal mucosal graft (BMG) the inner mucosal surface of the cheek marked for the required length of the graft [Figure 3a and b]. A solution of lignocaine with adrenaline was injected under the graft to enhance hemostasis and to raise the area to be harvested. Then it was harvested from the inner cheek avoiding injury to the Stenson's duct without any stitches on the donor site. If the required graft length was longer, then harvesting was also done from the contralateral cheek [Figure 4a and b]. The graft was defatted with fine scissors and tailored according to the length of the stricture [Figure 6a and b].

In both cases, the harvested graft was spread, fixed and quilted to the overlying tunica albuginea of the corporal bodies opposite to the stricturotomy site on a 16 Fr, Foley's catheter as described in the literatures.<sup>[4,5]</sup>

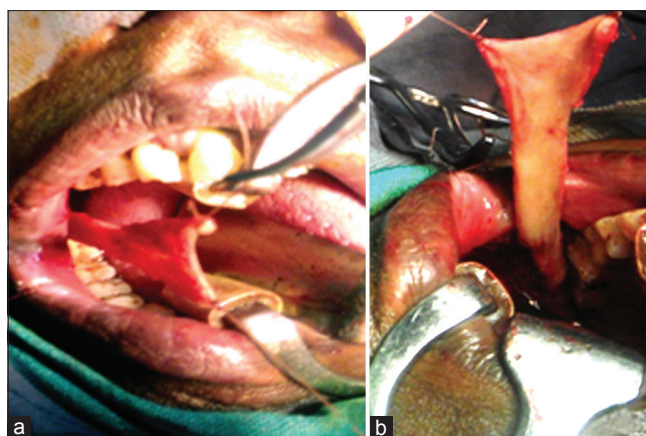
#### Postoperative management and follow-up

Injectable antibiotics (ceftriaxone, amikacin, and metronidazole) were given for 5 days postoperatively and changed to oral ciprofloxacin 500 mg and ornidazole 200 mg BD subsequently. Injectable analgesic (diclofenac sodium 75 mg BD) was given for initial 2 days postoperatively and then changed to oral formulation. Patients were advised to continue povidone iodine mouthwash thrice daily. The perineal wound was left open from postoperative day-4 onwards. The perineal wound was closed by absorbable sutures, so there was no need for suture removal.

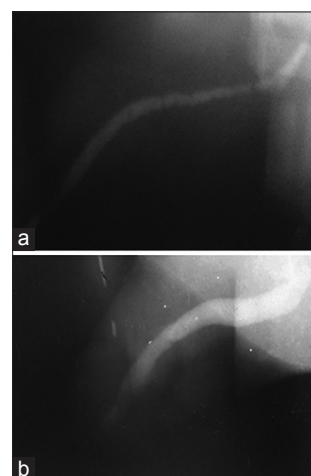
Orally, liquid diet was allowed on postoperative day 1 and from postoperative day 2 patients were allowed to take his normal diet. Patients were routinely discharged on the seventh postoperative day if otherwise fit. The catheter was removed if there was no extravasation of contrast in the pericatheter urethrography at 3 weeks. If extravasation was present, the catheter was kept for another 2 weeks. The patients were then followed at 3 months and 6 months with uroflowmetry. If the uroflowmetry was unsatisfactory, then urethrogram was done. All the patients were advised to review in the urology OPD or contact telephonically if they develop any complication.

## RESULTS

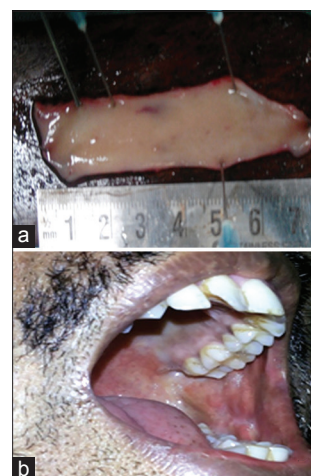
On prospective analysis of 60 patients (30 BMG and 30 lingual



**Figure 4:** (a and b) Buccal mucosal graft harvesting from inner side of cheek



**Figure 5:** (a) Preoperative retrograde urethrogram of a patient showing pan anterior urethral stricture plan for buccal mucosal graft urethroplasty. (b) Postoperative retrograde urethrogram after buccal mucosal graft urethroplasty



**Figure 6:** (a) Buccal mucosal graft. (b) Buccal mucosa harvest site after 1-month

mucosal graft [LMG]) who underwent urethroplasty by dorsal onlay free oral graft from February 2013 to September 2014, the following observations were noted.

In reference to the stricture etiology, BXO was the leading cause in both BMG and LMG groups, with more than half the patients attributed to it. Infective, traumatic, iatrogenic, and idiopathic were the other causes as seen in Figure 7a [Table 1].

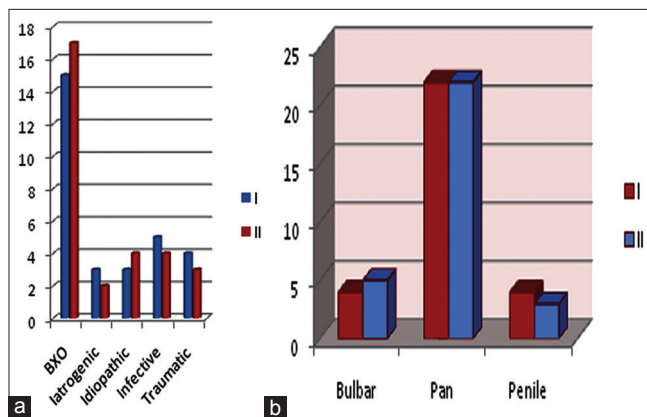
Pan urethral strictures were the most common in both BMG and LMG groups at 70% and 73.3%, respectively. The rest had either a penile or a bulbar urethral stricture, as shown in Figure 7b.

The mean length of stricture as measured intraoperatively was 9.2 cm (range: 3.8–14.8 cm) in BMG group [Figure 5a] and 9.6 cm (range: 3.5–15.5 cm) in LMG group patients [Figure 2a].

The length of buccal/lingual mucosa harvested was measured intraoperatively. The mean length of mucosa was 10.23 cm in the BMGU (Group 1) in comparison to 10.10 cm in the LMGU (Group 2).

Mean follow-up was 15.2 mo (median: 16.3 mo; range: 6–19 mo) in Group 1 and 14.1 mo (median: 14.5 mo; range: 7–19 mo) in Group 2.

The intraoperative parameters recorded during surgery were the duration of surgery, graft harvesting time and blood loss.



**Figure 7:** (a) Graph showing distribution of etiology of stricture. (b) Graph showing distribution of site of stricture

**Table 1: Stricture characteristics and distribution**

Patient characteristics	Group 1(BMGU)	Group 2(LMGU)
Age of the patient (mean, years)	29.9	29.7
Aetiology of stricture		
Balanitis xerotica obliterans	15	17
Inflammatory	5	4
Iatrogenic	3	2
Traumatic	4	3
Idiopathic	3	4
Site of stricture (%)		
Penobulbar urethra	21 (70)	22 (73.3)
Penile urethra	4 (13.3)	5 (16.6)
Bulbar urethra	5 (16.6)	3 (10)

BMGU: Buccal mucosal graft urethroplasty, LMGU: Lingual mucosal graft urethroplasty

The duration of surgery was observed to be slightly greater in those undergoing BMGU (Group 1) in comparison to those having LMGU (Group 2) with mean operative durations of 175.85 min (mean graft harvesting time 38 min) and 161.25 min (mean graft harvesting time 25 min), respectively. Intraoperative blood loss was found to be a little more in the BMGU (Group 1) in comparison to the LMGU (Group 2) with mean blood loss of 180 ml and 176.5 ml, respectively. These intraoperative parameters were not statistically significant ( $P > 0.05$ ). Mean duration of hospitalization was 5.9 days (range 5–9) and 6.5 days (range 6–8) in Groups 1 and 2, respectively.

The mean Qmax in both the groups showed improvement after surgery. In Group 1, the mean Qmax improved from 8.6 ml/min to 29.56 ml/min (mean improvement 18.64) at 3 months postoperatively and in Group 2, the mean Qmax changed from 7.43 ml/min to 30.29 ml/min (mean improvement 21.40). Within the groups, the improvement seen in mean Qmax was found to be statistically highly significant ( $P < 0.001$ ). Between the two groups, the difference in improvement of Qmax was not found to be statistically significant ( $P > 0.05$ ).

The AUA symptom score decreased from a mean of 21.23 to 5.3 (mean decreased 16.1) and 20.67.5 to 5.37 (mean decreased 15.3), respectively, in Groups 1 and 2. Within the groups, decrease in symptom score was found to be statistically highly significant ( $P < 0.013$ ). Between the two groups, the difference in the decrease in symptom score was not found to be statistically significant ( $P > 0.05$ ) [Table 2].

Pericatheter study was done after 3 weeks of urethroplasty. Six patients of Group 1 and five patients of group 2 showed extravasation of contrast, which were managed successfully by extended catheterization for another 2 weeks. Repeat contrast study showed no leak and then voiding trial was given.

In Group 1, 3 patients developed stricture at the anastomotic site (1 distal anastomotic site, 2 proximal anastomotic sites), out of which 1 patient was managed with urethral dilatation and 2 patients required one attempt of visual internal urethrotomy. Four patients developed metal stenosis which was managed with metal self-calibration (3 patients) or meatotomy (1 patient). In Group 2, 2 patients developed stricture at the anastomotic site. Both patients were managed successfully with one attempt of visual internal urethrotomy. Four patients developed metal stenosis which required meatotomy in 3 patients and 1 patient with flimsy adhesions were managed with metal self-calibration.

At 3 months postoperative, 2 patients in Group 1 and 3 in Group 2 had a poor flow rate ( $Q_{max} < 15$  ml/min) and were declared as a failure. All these patients had wound infection and graft necrosis in the early postoperative period. At 6 months,

three more patients (two in Group I and two in Group 2) were observed to have a poor flow rate ( $Q_{max} < 15$  ml/min). Among these patients, two patient one in each group had developed wound hematoma in the early postoperative period. In the other patient, no cause could be determined for the failure. The overall success rates for BMG and LMG urethroplasty were 86% and 83%, respectively. Post operative urethrogram showed a good caliber urethra at 6 months in both groups [Figures 2b and 5b].

### Donor site evaluation

The length of buccal/lingual mucosa harvested was measured intraoperatively. The mean length of mucosa was 10.23 cm in the BMGU (Group I) range: 5.8–15.9 cm) (in comparison to 10.10 cm (range: 4.8–16.2 cm) in the LMGU (Group 2). Lingual mucosa width was slightly lesser than buccal mucosa.

96.6% of Group I patients and 90% of Group 2 patients experienced pain at the donor site on postoperative day 1, which subsided completely by postoperative days 5–6 in both groups except for in 3 patient in Group I in whom it persisted even after 3 months of follow-up.

Difficulty in tongue movement and slurring of speech was seen in 11 patients in Group 2, proportional to the length of graft harvested. This complication decreased as the pain subsided. The majority of patients had normal movement of tongue and speech by postoperative days 4 or 5. There was no bleeding hematoma or infection at donor site at the time of discharge.

Long-term complications (after 3 months) at donor site in the form of persistent pain at graft site, perioral numbness, tightness of mouth, salivary disturbance, scarring of the cheeks seen in Group I only [Table 3].

### DISCUSSION

According to Turner Warwick, the urethra is the best substitute for urethra.<sup>[6]</sup> However, this is only possible when <2 cm of the urethra is to be excised, and the end-to-end anastomosis is performed.

The use of local genital skin can cause penile/glans torsion, subcutaneous deformities, and chordee. Hence, the free extragenital tissue is needed to perform urethroplasty. An oral mucosal graft is considered the best tissue providing excellent clinical results.<sup>[7]</sup>

Urethroplasty techniques are continuously improving with advancements in the field of substitution urethroplasty.

The ventrolateral aspect of the tongue offers mucosal tracts that are up to 7–8 cm long, depending on the tongue dimensions and has constant availability. Buccal mucosa and lingual mucosa

**Table 2: Comparison between groups I and II**

Characteristics	Group I	Group II	P value
stricture length, cm	9.2 (3.8-14.8)	9.6 (3.5-15.5)	0.735
Graft length, cm	10.23 (4.3-15.6)	9.8 (4.5-16)	0.627
Preoperative Qmax	8.6 (4-11)	7.43 (4-10.3)	0.085
Postoperative Qmax (3 month)	29.56 (23-36)	30.29 (24-40)	0.63
AUA symptom score			
Preoperatively	21.23 (14-29)	20.67 (13-29)	0.71
Postoperatively	5.3 (4-8)	5.37 (3.2-8.6)	0.83
Success rate	86.6%	83.3%	0.91

**Table 3: Complications in groups I and II**

Complications at urethroplasty site	Group 1	Group 2
Extravasation of contrast on pericatheter study at 3 <sup>rd</sup> week	6	5
Wound infection	2	3
Meatal stenosis	4	4
Stricture at anastomotic site	3	2
Immediate complications (first 7 postoperative days) at donor site		
Pain at donor site	27	28
Slurring of speech	0	11
Numbness over the ventral aspect of anterior half of the tongue	0	1
Salivatory disturbance	4	0
Delayed feeding	3	1
Swollen cheeks	5	0
Difficulty in mouth opening	4	0
Long-term complications (after 3 months) at donor site		
Tightness of mouth	3	0
Perioral numbness	4	0
Salivatory disturbances	3	0
Persistent pain at graft site	4	0
Scarring of cheek	1	0

has the same embryologic origin, are easy to harvest, have favorable immunologic properties (resistance to infection) and tissue characteristics (thick epithelium, high content of elastic fibers, thin lamina propria, and rich vascularization) that are favorable properties for imbibitions, inosculation, and revascularization of the graft.<sup>[2]</sup>

LMG is easy to harvest (as the whole of the tongue can be pulled out of the mouth) and provides very long continuous grafts. This is especially advantageous over BMG harvesting in patients who had difficulty in mouth opening. The lateral aspect of the lingual mucosa has no particular functional features and almost half of the tongue tissue can be used as donor tissue, as in cancer of the tongue, without imposing any functional limitations on it.<sup>[8]</sup>

In our study, we have compared LMG urethroplasty with BMG urethroplasty in terms of success rates, duration of postoperative hospitalization, blood loss, mean postoperative Qmax at 3 months and 6 months, and the mean postoperative AUA symptom score. There were insignificant differences for all the above parameters between the two groups (all have  $P > 0.05$ ). These findings were

**Table 4: Other studies suggesting BMG has more donor site complication than LMG**

Author and year	No. of pt	Site of graft	Early complication	Long term complication
Dublin <i>et al.</i> 2004 <sup>[11]</sup>	30	Cheeks	Tightness of mouth, pain at graft site, perioral numbness, swollen cheek	Tightness of mouth; oral numbness, recurrent mouth ulcers at graft site, reduced bucco-gingival space, rough sensation over harvesting site, inability to purse lips to whistle, fluid dripping from the angle of the mouth
Bargbli <i>et al.</i> 2005 <sup>[10]</sup>	90	Cheek	Pain, swelling, bleeding	Perioral numbness, discomfort due to sutures, discomfort due to scar, infections, difficulty with mouth opening, difficulty to smile, changes in face physiognomy; dry mouth
Yongolo 2005 <sup>[3]</sup>	13	Cheeks	Bleeding, hematoma, Infection, pain, cheek swelling, difficulty in feeding,	None
Bargbli <i>et al.</i> 2008 <sup>[12]</sup>	10	Tongue	None	None
Simonato <i>et al.</i> 2006 <sup>[2]</sup>	8	Tongue	Slight oral discomfort (100%)	None
Song <i>et al.</i> 2008 <sup>[13]</sup>	10	Tongue	None	None

BMG: Buccal mucosal graft, LMG: Lingual mucosal graft

similar to previously done studies like the one reported by Kumar *et al.*<sup>[9]</sup>

However, in our study, the donor site complications were more in BMG group. The main long-term donor site complications of BMG were a persistent pain at graft site, perioral numbness, and difficulty in opening the mouth. Our findings are similar to those reported by Barbagli *et al.* and Dublin *et al.* but differed from the findings of Yongolo, who reported only short-term complications after BMG harvesting without any long-term complications.<sup>[10,11,3]</sup>

As shown in Table 3, in the LMG group we never observed any major intraoral complications, such as persistent pain at the graft site, perioral numbness, and difficulties with mouth opening, deviations, or retractions. Patients with the graft harvested from the tongue reported difficulty in tongue protrusion and slurring of speech for <7 days. This was in sync with findings of previous studies done by Barbagli *et al.*, Song *et al.* and Simonato *et al.* who reported minimal or no complications after LMG harvesting.<sup>[12,13,2]</sup> These findings are summarized in Table 4.

## CONCLUSION

Buccal mucosa and lingual mucosa are equally good for substitution urethroplasty, but BMG is not without donor site complication. LMG provides long grafts and is easy to harvest. Moreover, have minimal immediate or short-term donor site complications with no long-term complications. Hence, LMG may be used to substitute or supplement the already established procedure of BMG urethroplasty with minimal complications. With promising similar results from multicenter trials with larger sample size, LMG urethroplasty may become the gold standard in the future.

## Financial support and sponsorship

Nil.

## Conflicts of interest

There are no conflicts of interest.

## REFERENCES

- McKillop C. Interview with Dr. Guido Barbagli substitution urethroplasty: Which tissue and techniques are optimal for urethral replacement. *Eur Urol* 2007;52:602-4.
- Simonato A, Gregori A, Lissiani A, Galli S, Ottaviani F, Rossi R, *et al.* The tongue as an alternative donor site for graft urethroplasty: A pilot study. *J Urol* 2006;175:589-92.
- Yongolo CM. Initial experience of buccal mucosa urethroplasty in Tanzania. *East Cent Afr J Surg* 2005;10:67-71.
- Barbagli G, Selli C, Tosto A, Palminteri E. Dorsal free graft urethroplasty. *J Urol* 1996;155:123-6.
- Barbagli G, Selli C, di Cello V, Mottola A. A one-stage dorsal free-graft urethroplasty for bulbar urethral strictures. *Br J Urol* 1996;78:929-32.
- Gupta NP, Ansari MS, Dogra PN, Tandon S. Dorsal buccal mucosal graft urethroplasty by a ventral sagittal urethrotomy and minimal-access perineal approach for anterior urethral stricture. *BJU Int* 2004;93:1287-90.
- Fiala R, Vidlar A, Vrtal R, Belej K, Student V. Porcine small intestinal submucosa graft for repair of anterior urethral strictures. *Eur Urol* 2007;51:1702-8.
- Guerrerosantos J, Dicksheet S, Ruiz-Razura A. Free tongue composite graft for correction of a vermilion defect. *Plast Reconstr Surg* 1985;76:451-4.
- Kumar A, Das SK, Trivedi S, Dwivedi US, Singh PB. Substitution urethroplasty for anterior urethral strictures: Buccal versus lingual mucosal graft. *Urol Int* 2010;84:78-83.
- Barbagli G, Palminteri E, Guazzoni G, Berdondini E, Difiore F, Domizio AS. The morbidity of buccal mucosa graft harvest from a cheek in adult patients. *J Urol* 2005;173 4 Suppl:33. [abstr 122].
- Dublin N, Stewart LH. Oral complications after buccal mucosal graft harvest for urethroplasty. *BJU Int* 2004;94:867-9.
- Barbagli G, De Angelis M, Romano G, Ciabatti PG, Lazzeri M. The use of lingual mucosal graft in adult anterior urethroplasty: Surgical steps and short-term outcome. *Eur Urol* 2008;54:671-6.
- Song LJ, Xu YM, Hu XY, Zhang HZ. Urethral substitution using autologous lingual mucosal grafts: An experimental study. *BJU Int* 2008;101:739-43.